

# Continuous Psoas Compartment Block for Postoperative Analgesia After Total Hip Arthroplasty: New Landmarks, Technical Guidelines, and Clinical Evaluation

Xavier Capdevila, MD, PhD, Philippe Macaire, MD, Christophe Dadure, MD, Olivier Choquet, MD, Philippe Biboulet, MD, Yves Ryckwaert, MD, and Françoise d'Athis, MD

Department of Anesthesia and Critical Care Medicine, Lapeyronie University Hospital, Montpellier, France; Department of Anesthesia, Clinique du Parc, Lyon, France; and Department of Anesthesia, La Conception University Hospital, Marseille, France

A computed tomographic scan was obtained in 35 patients to measure the depth and the relationship of the branches of the lumbar plexus to the posterior superior iliac spine projection and the vertebral column. In addition, we prospectively studied 80 patients scheduled for total hip arthroplasty who received a continuous psoas compartment block (CPCB) in the postoperative period. CPCB was performed after surgical procedures by using modified Winnie's landmarks and nerve stimulation. From 5 to 8 cm of catheter was inserted. Radiographs were obtained after injection of 10 mL of contrast medium. An initial loading dose (0.4 mL/kg) of 0.2% ropivacaine was injected, followed by continuous infusion of 0.2% ropivacaine for 48 h. The depth of the lumbar plexus and the distance between the lumbar plexus and the L4 transverse process were measured. Visual analog scale values of pain at 1, 12, 24, and 48 h were obtained at rest and during mobilization. Amounts of rescue analgesia were also recorded. Sensory blockade of the principal branches of the lumbosacral plexus was noted at 1 and 24 h, as were adverse events related to the technique. There was a significant difference between men and women in depth of the lumbar plexus (median values, 85 vs 70 mm for men and women,

respectively). There was a positive correlation between the body mass index and skin-lumbar plexus distances. In contrast, there was no difference regarding the distance between the transverse process of L4 and the lumbar plexus. The catheter tip lay within the psoas major muscle in 74% of the patients and between the psoas and quadratus lumborum muscles in 22%. In three patients, the catheter was improperly positioned. At 1 h, sensory blockade of the femoral, obturator, and lateral femoral cutaneous nerves was successful in, respectively, 95%, 90%, and 85% of patients. At 24 h, these rates were 88%, 88%, and 83%, respectively. During the 48-h study period, median visual analog scale values of pain were approximately 10 mm at rest and from 18 to 25 mm during physiotherapy. Five patients received 5 mg of morphine at 1 h. Five cases of unilateral epidural anesthesia were noted after the bolus injection. We conclude that CPCB with 0.2% ropivacaine allows optimal analgesia after hip arthroplasty, with few side effects and a small failure rate. Before lumbar plexus branch stimulation and catheter insertion, anesthesiologists should be aware of the L4 transverse process location and lumbar plexus depth.

(Anesth Analg 2002;94:1606-13)

**A**fter total hip arthroplasty (THA), 50% of patients consider the postoperative pain at rest as severe and report it to be exacerbated during rehabilitation (1). Pain relief can be achieved by patient-controlled IV analgesia or by epidural analgesia (2). Unfortunately, these techniques are associated with

poor pain relief during movement, related side effects and technical problems (2,3), or both. Peripheral nerve blocks are useful in providing anesthesia and postoperative analgesia. Continuous three-in-one blocks improve postoperative analgesia (3,4), but cases of unsuccessful sensory blockade of the obturator and lateral femoral cutaneous (LFC) nerves have been observed (5-7). The obturator nerve has sensory branches for the hip and knee joints (8). These results may explain the lack of interest in the continuous three-in-one block expressed by some authors (9,10). Furthermore, in the latter technique, the catheter is situated near the surgical site (3). Psoas compartment block techniques are reliable in their ability to block all branches of the lumbar plexus (LP) (5,11,12). In association with sciatic nerve block, they provide good

Supported, in part, by the Association pour le Développement et la Recherche en Anesthésie Réanimation, CHU Lapeyronie, Montpellier, France.

Presented in part at the annual meeting of the American Society of Anesthesiologists, San Francisco, CA, October 14-18, 2000.

Accepted for publication January 16, 2002.

Address correspondence and reprint requests to Xavier Capdevila, MD, PhD, Département d'Anesthésie et Réanimation A, Hôpital Lapeyronie, 371 Avenue du Doyen Gaston Giraud, 34295 Montpellier Cedex, France. Address e-mail to x-capdevila@chu-montpellier.fr.

anesthesia for hip fractures (13). After THA, despite their efficacy, psoas compartment blocks provide postoperative analgesia for only a limited period of time (14,15). Continuous psoas compartment blocks (CPCBs) have been described (16,17) and used for perioperative analgesia in patients with hip fractures (18). The CPCB appears to be an appropriate technique for effective and safe pain relief. Nevertheless, several reports in the literature of major adverse events after single-shot psoas compartment blocks (19-21) prompted us to reanalyze landmarks and technical guidelines. The purpose of this study was to evaluate the feasibility and efficacy of CPCB after THA in light of this new analysis of the technique.

## Methods

### *Computed Tomographic Scan Study*

After institutional approval and written, informed patient consent, 35 adults scheduled for radiological investigation of low-back pain or knee or hip disorders were included in the study. The lumbosacral region of all of these patients had a radiographic aspect that was considered to be normal. Axial transverse computed tomographic (CT) sections of the lumbosacral region (i.e., 70 LP), essentially centered on the L3, L4, L5, and S1 vertebrae, were used to determine the following values: 1) the distance between a line passing through the middle of the spinous processes of L4 and L5 to a parallel line through the posterior superior iliac spine (PSIS); 2) the distance from the former line to a line passing through the LP located in the psoas major muscle; and 3) the depth of the LP (its distance from the skin). The 2 LPs were actually located by the radiologist in 29 patients (58 LPs), and in 6 patients (12 LPs) they were assumed to lie inside the psoas major muscle at the junction of the posterior third and the anterior two thirds.

### *Clinical Study*

Eighty consecutive ASA physical status I, II, and III patients scheduled for total hip replacement ( $n = 57$ ) or revision ( $n = 23$ ) were included in this multicenter prospective study once institutional approval and written, informed consent were obtained. The postoperative pain management program included CPCB for all patients. All the patients were orally premedicated with 0.1 mg/kg of midazolam. Intraoperative general anesthesia was induced for all patients with 3 mg/kg of IV propofol and 0.5  $\mu\text{g}/\text{kg}$  of sufentanil. Patients underwent endotracheal intubation, and mechanical ventilation was applied for the duration of surgery. Anesthesia

was maintained with 60% nitrous oxide in oxygen, 0.75%-1.25% isoflurane end-tidal concentration, and 0.3  $\mu\text{g}/\text{kg}$  of IV sufentanil given over 30 min, followed by continuous infusion at 0.10  $\mu\text{g} \cdot \text{kg}^{-1} \cdot \text{h}^{-1}$ , which was stopped 30 min before the end of surgery.

Once the patients were awakened and extubated after the surgical procedure, CPCB was performed by using a nerve stimulator (Stimuplex<sup>®</sup>; Braun, Geisingen, Germany) connected to a new nontraumatic 18-gauge insulated needle (Plexolong<sup>®</sup>; Pajunk, Melsungen, Germany). In light of the results of the preliminary CT scan study, the landmarks of Winnie et al. (22) were slightly modified for use in this CPCB trial. Patients were turned to the lateral position, with the operated side uppermost. The insulated needle was inserted at the junction of the lateral third and medial two thirds of a line between the spinous process of L4 and a line parallel to the spinal column passing through the PSIS (Fig. 1). The spinous process of L4 was estimated to be approximately 1 cm cephalad to the upper edge of the iliac crests. With a starting output of 2 mA (frequency, 1 Hz; time, 100  $\mu\text{s}$ ), the needle was advanced perpendicularly to the skin until contact with the transverse process of L4 was obtained. The needle was then pulled back 0.2 cm and advanced under the transverse process until quadriceps femoris muscle twitches were elicited (i.e., cephalad patellar movements). The position was judged adequate when quadriceps contractions were still elicited by impulses of 0.3 to 0.5 mA. The depth of the LP (estimated when the contractions were elicited at 0.5 mA) and the distance between the LP and the L4 transverse process were noted, as was the body mass index (BMI) of each patient. The needle bevel was oriented caudally and laterally, the psoas compartment was distended with 5 mL of saline, and a 20-gauge multiperforated catheter was introduced through the needle and advanced 5-8 cm distally to the needle tip. Ten milliliters of contrast medium (Iopamidol 300<sup>®</sup>; Shering Pharmaceutical, Lys-Lez-Lannoy, France) was injected into the catheter, and an anteroposterior radiograph of the pelvic region was obtained within 5 min. The radiographs were interpreted by two blinded physicians, one of whom was a radiologist. The catheter location was noted.

An 0.4 mL/kg initial loading dose of 0.2% ropivacaine was then injected via the catheter over a 2-min period before a continuous infusion of 0.2% ropivacaine was administered at 0.15 mL  $\cdot \text{kg}^{-1} \cdot \text{h}^{-1}$  for 48 h. The doses of local anesthetics were not evaluated by dose-ranging studies. The arterial blood pressure was measured at 3-min intervals, and electrocardiographic tracings, respiratory rate, pulse oximetry, and end-tidal  $\text{CO}_2$  were monitored continuously during the procedure. Sensory blockade was evaluated at 1 and 24 h by using cold perception and light touch tests. Testing was performed bilaterally from T8 to L1,

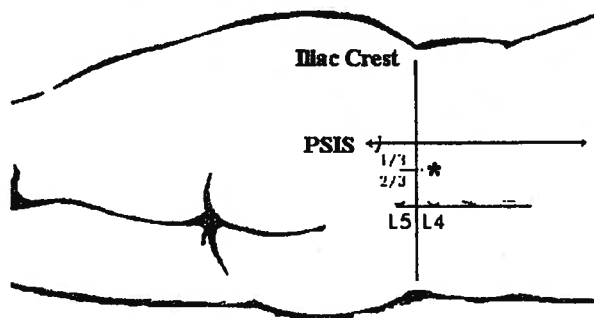


Figure 1. Estimation of the point of puncture of continuous psoas compartment block by using the preliminary computed tomography studies. PSIS = posterior superior iliac spine. \*Point of puncture.

and the sensory distribution of the femoral nerve (anterior aspect of the thigh), genitofemoral nerve (anterior surface of the proximal portion of the thigh), LFC nerve (lateral aspect of the thigh), obturator nerve (medial and posterior aspect of the knee), and S1 root were verified. The results of these sensory tests were reported as either yes (complete sensory blockade) or no (absent or partial sensory blockade). Pain at rest and during rehabilitation (physiotherapy 4 h twice a day with continuous passive motion machines allowing a flexion of 0° to 60° the first postoperative day and of 0° to 70° the following days) were evaluated at 1, 12, 24, and 48 h by using a visual analog scale (VAS) ranging from 0 mm (no pain) to 100 mm (worst imaginable pain). Ketoprofen (100 mg IV twice daily) was systematically administered to all patients during the study period.

If pain control was considered insufficient during the studied period (i.e., 40 mm or more on the VAS), a subcutaneous injection of morphine (0.1 mg/kg) was administered as rescue analgesia. The amount of morphine was noted. All adverse effects were noted. General adverse effects, including arterial hypotension, sedation, urinary retention, epidural anesthesia, and dysesthesias, were distinguished from local adverse effects, which included skin hematoma and blood loss and catheter occlusion or kinking.

Statistical analysis was performed with SAS version 6.11 software (SAS Institute, Cary, NC). The quantitative anthropometrics data and CT scan measurements were expressed as medians (extremes). VAS values were expressed as medians (10th, 25th, 75th, and 90th percentiles). Analysis of variance for repeated measurements was used to compare values recorded at different times, and Mann-Whitney *U*-tests were used for nonparametric data. Spearman's coefficient of correlation was applied to analyze correlations between the measured skin-LP distance, spinous process-LP distance, spinous process-PSIS distance, transverse

Table 1. Population and Computed Tomographic Scan Data

Variable	Men (n = 16)	Women (n = 19)
Age (yr)	62 (20-81)	59 (24-77)
Weight (kg)	81 (61-97)	63 (44-88)*
Depth LP (mm)	83.50 (61-101)	71 (57-93)*
Distance SP/PSIS (mm)	49.50 (24-65)	37.50 (12-49)*
Distance SP/LP (mm)	38 (16-42)	28 (8-31)*
Ratio	0.68 (0.6-0.74)	0.67 (0.6-0.8)

Values expressed as median (range).  
LP = lumbar plexus; SP = spinous process; PSIS = line through the posterior superior iliac spine; Ratio = distance SP-LP/distance SP-PSIS.

\* *P* < 0.05, women versus men.

process-LP distance, and BMI or weight. A significance threshold of *P* < 0.05 was retained.

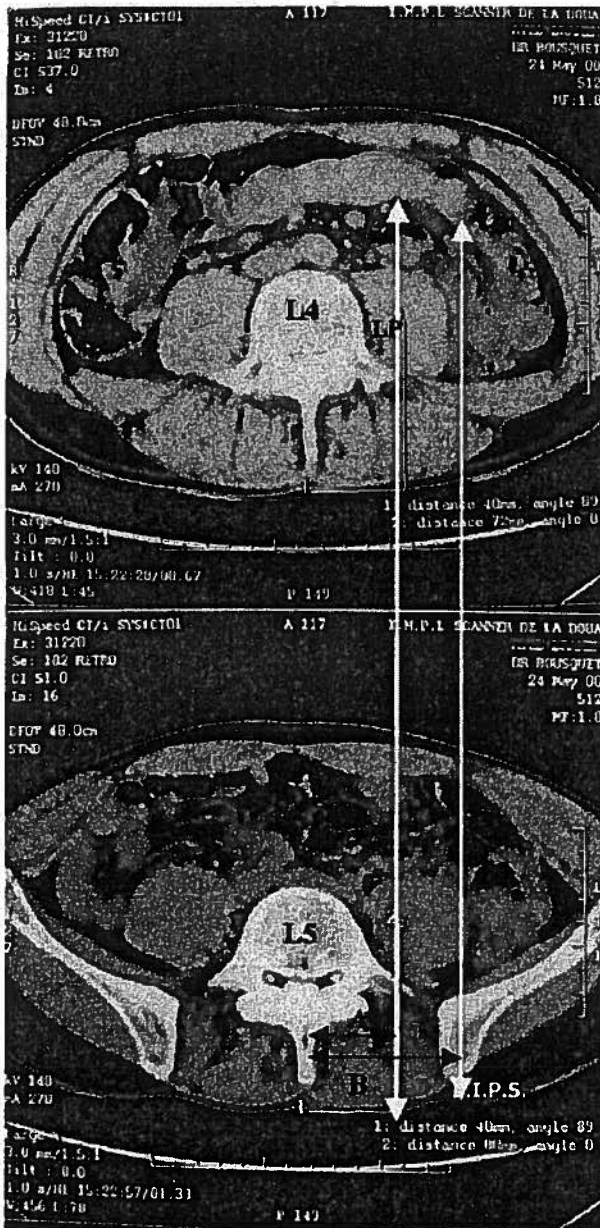
## Results

### CT Scan Study

Sixteen men and 19 women were included in the CT scan study. Seventy LPs were analyzed. The CT measurements are shown in Table 1. Branches of the LP were localized on the line through the PSIS parallel to the vertebral column (Winnie's landmarks) in none of the subjects (Fig. 2). The distances from the middle of the spinous processes of L4 and L5 to the LP and to the line passing through the PSIS in men differed from those in women and were positively correlated to the weight of patients (0.93; *P* < 0.05). There were no sex-related differences, nor was there a correlation with BMI or weight in the ratio between the distance of the spinous process-LP and the distance from the spinous process to the line through the PSIS parallel to the spinal column (median values, 0.68 vs 0.67). This ratio determines the point of puncture of the CPCB. The depth of the LP was significantly more in men, and this was positively correlated with the weight of the patients (0.91; *P* < 0.05). Consequently, the ratio of the distance of the spinous process-LP to the distance of the spinous process-PSIS and the estimated depth of the LP should be taken into account when administering CPCB.

### Clinical Study

Forty men and 40 women were included in the CPCB trial. Fifty of them were ASA status I, 25 were ASA status II, and 5 were ASA status III patients. Patient data are presented in Table 2. Differences between men and women were noted concerning weight, height, and BMI values. The distance between the LP and the L4 transverse process was comparable (median value, 18 mm) in both sexes despite a difference between men and women concerning the depth of the LP (median values, 85 vs 70 mm; *P* < 0.05) (Fig. 3). LP



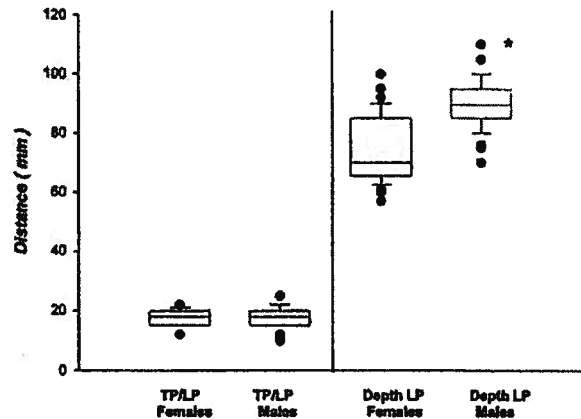
**Figure 2.** Computed tomographic scan determination of the distance between spinous processes of L4 and L5 and lines through the lumbar plexus (LP) (top) and through the posterior superior iliac spine (bottom; landmarks of Winnie et al.). The median value of the ratio between these two distances (A and B) was 0.67. Consequently, it was warranted to situate the cutaneous puncture point for the continuous psoas compartment block at the junction of the medial two thirds and lateral third of the line between the spinous process of L4 and the line through the posterior superior iliac spine parallel to the spinal column.

depth values located by nerve stimulation were correlated with BMI values (0.93;  $P < 0.05$ ). In 74% of the patients, the catheters were located within the psoas major muscle, and in 22% they were located under the

**Table 2.** Demographic Characteristics of Patients

Variable	Men (n = 40)	Women (n = 40)
Age (yr)	64 (21-85)	62 (31-95)
Weight (kg)	85 (65-113)	66 (44-130)*
Height (cm)	175 (163-185)	161 (150-170)*
BMI (kg/m <sup>2</sup> )	28.4 (22.3-38.2)	24.4 (16.2-38.9)*

Values expressed as median (range).  
BMI = body mass index.  
\*  $P < 0.05$ , women versus men.



**Figure 3.** Depth of the lumbar plexus (LP) and the distance between the lumbar plexus and the transverse process (TP) in men and women. Despite the difference in depth of the lumbar plexus, the consistency of the distance between the transverse process and the lumbar plexus warrants consideration of contact with the transverse process of L4 as obligatory in the technique.

fascia iliaca in the area between the psoas and quadratus lumborum muscles (Fig. 4, A and B). The catheter tip was threaded to an improper location in three patients. One catheter was located in the abdominal cavity, one in a retroperitoneal position, and one in the L4-5 intervertebral disk. They were immediately removed after their opacification.

At 1 h, sensory blockade of the femoral nerve, obturator-genitofemoral nerves, and LFC was successful in, respectively, 95%, 90%, and 85% of the patients. At 24 h, these same rates were 88%, 88%, and 83%, respectively. None of the patients had sensory blockade in the S1 territory. The 25th-75th percentiles and median VAS pain values at rest and during physiotherapy are shown in Figure 5, A and B. These values were very low during the 48-h duration of the study (median values were close to 10 mm at rest and ranged from 15 to 25 mm during movement). Four patients who showed an anesthetic insufficiency of the femoral nerve distribution received 5 mg of morphine at 1 h, as did one patient who showed an anesthetic insufficiency of the obturator nerve distribution. Adverse effects of the nerve block included hematoma at

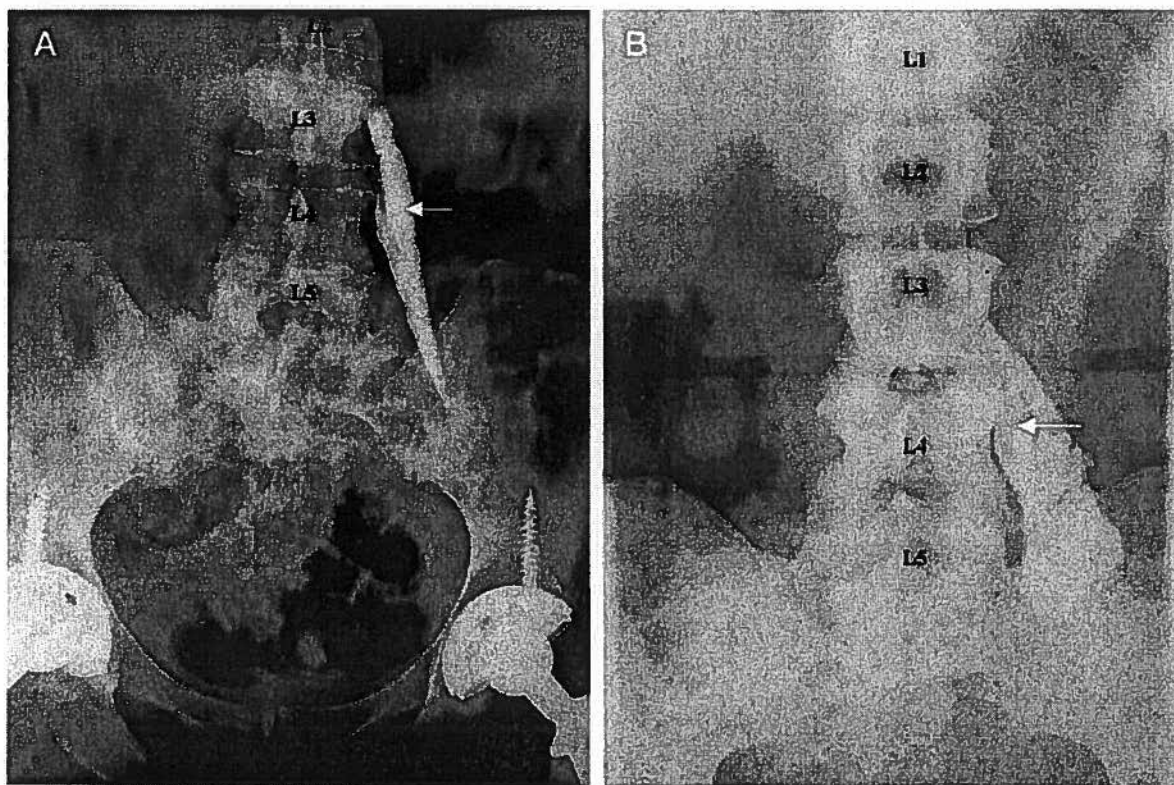


Figure 4. A, Catheter (arrow) located within the psoas major muscle. B, Catheter (arrow) located under the fascia iliaca, in the area between the psoas and quadratus lumborum muscles

the point of puncture in one patient, nausea and vomiting in three patients, paresthesia in the LFC nerve distribution during 24 h in one patient, and unilateral epidural anesthesia in five patients (6.5%). No patient exhibited clinical evidence of local anesthetic toxicity.

## Discussion

In this study, the authors demonstrated that CPCB performed with the aid of a nerve stimulator and with 0.2% ropivacaine allows optimal analgesia after THA, with few sensory block failures and few side effects. New landmarks were defined to facilitate and ensure the safety of CPCB catheter insertion. Before stimulation of the LP and catheter threading, localization of the L4 transverse process location is an obligatory step.

Thorough knowledge of anatomy and an understanding of the original description of the techniques is necessary for proper use of regional anesthesia. The posterior approach to the LP is no exception to this rule. The posterior L4 approach was chosen for this trial because the approach proposed by Chayen et al. (11) has been implicated in an excessive number of peridural anesthetics and the L3 approach appears dangerously close to the inferior pole of the ipsilateral

kidney (21). Regarding the L4 approach, Winnie et al. (22) proposed as the point of puncture the intersection of a line joining the iliac crests and a line parallel to the spine and passing through the PSIS. However, clinical experience with the latter technique and the literature on LP anatomy with respect to regional anesthesia (8,23,24) have shown this point of puncture to be overly lateral. The results of our study confirm this finding. A puncture perpendicular to the skin along a line parallel with the spine passing through the PSIS would not have gone through the LP in any of the patients we studied. In some cases, it would even have passed lateral to the psoas muscle (Fig. 2). Farny et al. (23) have already called attention to this point, reporting that a puncture situated more than  $6.4 \pm 1.6$  cm from the spinous process (lateral border of the psoas muscle) may completely miss the psoas major muscle. Three of our patients would have been subject to sensory block failure (distance from the spinous process-PSIS  $>60$  mm) if the landmarks of Winnie et al. (22) had been used. Recognizing this problem, Winnie et al. (22) recommended a slightly medial direction to the needle after puncture, bringing the tip closer to the spine. However, a more medially oriented needle can result in bilateral anesthesia or spinal anesthesia,

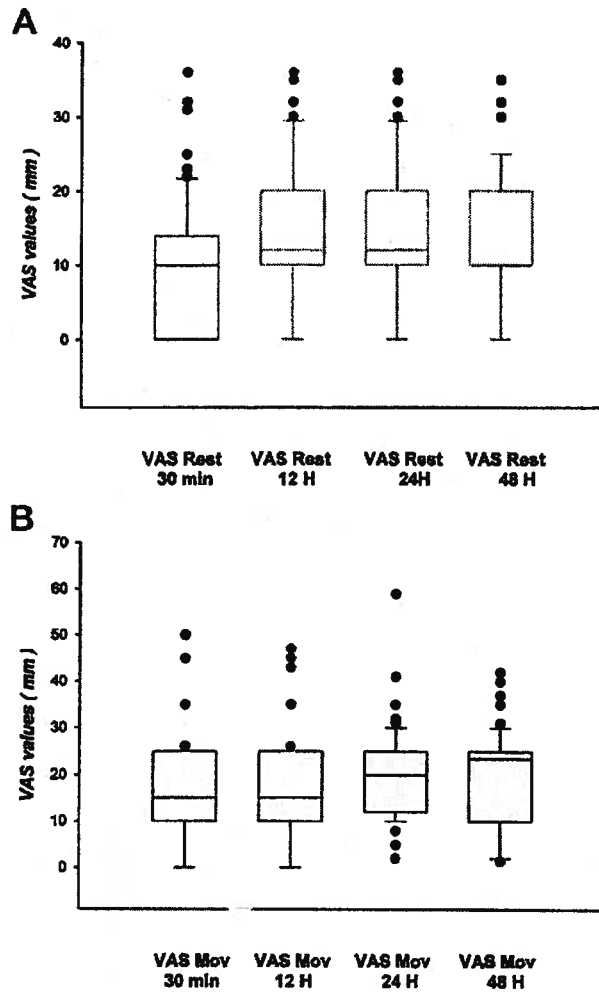


Figure 5. A, Visual analog scale (VAS) values at rest. The box represents the 25th-75th percentiles. The dark line is the median. The extended bars represent the 10th-90th percentiles, and the dark circles represent the values outside this range. B, VAS values during mobilization. The box represents the 25th-75th percentiles. The dark line is the median. The extended bars represent the 10th-90th percentiles, and the dark circles represent the values outside this range.

even if nerve stimulation is used for guidance (19), and should be avoided to prevent such adverse events.

The consistency of the ratio of the distance from the spinous process-LP to the distance from the spinous process-PSIS (0.67) in the men and women despite the weight or the BMI values in our study allows the puncture to be performed perpendicularly to the skin in all planes when this point of puncture is used. The use of new needles through which the catheter is inserted without the need for an intermediate cannula was quite appealing. The expected depth of the LP was also fundamental to consider before applying

neurostimulation and threading the catheter. In the literature, the depth of LP at the L4 level is reported to be from 5 cm (22) to  $9.9 \pm 2.1$  cm (23). These results were obtained from CT studies (23), real-time ultrasound guidance (25), or induced sensory blockade detected as paresthesias (22). No difference was noted between men and women in those studies, but there was a positive correlation between the LP depth and the BMI of patients (25). This study found a significant difference in the depth of the LP as shown by CT and by nerve stimulation in men compared with women, and the depth of the LP was positively correlated with weight or BMI. In addition, the distance between the transverse process and LP was quite constant (18 mm). This is why it is essential to obtain contact with the transverse process of L4 in the puncture procedure to optimize the neurostimulation and the threading of the catheter. Failure to obtain contact with the transverse process of L4 diminishes the reliability of the depth of the puncture and can lead to retroperitoneal injection if the needle is inserted deeper than  $11.6 \pm 3.0$  cm (23).

Fluoroscopy was used for the purposes of the studies. This technique may help physicians to locate the catheters because the catheters' displacement after threading is unpredictable. Unfortunately, this method seems difficult to apply in daily clinical practice. In our patients, 74% of the catheters were placed inside the psoas muscle. These results, in contradiction to the findings of Winnie et al. (22), confirm those of other authors (18,23) who have found that the LP is situated inside the psoas muscle rather than in the space between the psoas muscle and the quadratus lumborum muscle. Within the psoas muscle, the branches of the LP are close to each other (23). A variable three-in-one or LP block is expected. Despite the small concentration of local anesthetic used in this study (ropivacaine 0.2%), femoral and obturator nerve sensory block was obtained in 90% of patients at 1 hour and in more than 85% at 24 hours. These results, which are far superior to those often reported for the anterior approach, are consistent with the data in the literature with single-shot psoas compartment blocks (5). The small proportion of three-in-one blocks during the perivascular approach is principally caused by failure to attain the obturator nerve (5-7). There are two reasons for this failure. First, after a three-in-one block, the local anesthetic does not attain the obturator nerve with a concentration sufficient to achieve sensory blockade (6). Second, in this area, the obturator nerve courses behind the pelvic fascia behind the common iliac vessels and lateral to the hypogastric vessels. The usefulness of CPCB is related to this association of sensory blocks of the femoral and obturator nerves at 24 hours with a continuous infusion of ropivacaine, given that the sensory block tends to remain centered on the femoral nerve in fascia iliaca compartment

blocks (4). The obturator nerve distributes to the antero-medial portion of the hip joint (8) and part of the knee. The failure to achieve obturator nerve sensory block may in part account for certain inconsistencies in reports on the use of continuous three-in-one block for analgesia after knee (9,10) or hip (26) surgery.

In terms of postoperative analgesia after hip surgery, a single-shot three-in-one femoral nerve block provides only short-term benefit during the first few hours (27). Stevens et al. (15) have reported, in patients who underwent total hip replacement surgery, a reduction in VAS pain values at rest with the use of psoas compartment block (0.4 mL/kg of 0.5% bupivacaine with epinephrine) compared with the use of patient-controlled analgesia with morphine during the first 12 postoperative hours. Their consumption of morphine for rescue analgesia was also smaller. Although small, the median of the VAS values recorded by Stevens et al. (15) beginning at the 12th hour in the single-shot psoas compartment block group was always more than 20 mm. In this study, with a CPCB, the median VAS value of pain was close to 10 mm during the first 48 hours after surgery. Consequently, continuous peripheral nerve block appears to be warranted in such patients. Although its use is subject to debate (26), continuous three-in-one block after hip surgery has been evaluated. Singelyn and Gouverneur (3) and Singelyn et al. (4) have reported, concerning patients who had undergone THA, VAS values at rest of  $23 \pm 20$  mm at 24 hours and of  $11 \pm 17$  mm at 48 hours with continuous infusion of bupivacaine, sufentanil, and clonidine. However, the same authors reported values during mobilization of  $46 \pm 26$  mm at 24 hours and  $33 \pm 24$  mm at 48 hours. These values are more than those of this study during rehabilitation. This is most likely because of the sustained nature of the sensory block of the obturator nerve, the distribution of which is affected during physiotherapy. This early physiotherapy is recommended to limit adhesions, capsular contracture, and muscle atrophy, which may delay the ultimate functional outcome.

There are few studies on CPCB in the literature. Vaghadia et al. (16) used a Tuohy needle and the loss-of-resistance technique in three patients, in whom they infused 40 to 70 mL of local anesthetic through the catheter. Surgical anesthesia was obtained in every case, but the postoperative analgesia was not studied. Ben-David et al. (17) inserted a catheter after nerve stimulation, but they failed to describe the extent of block obtained and the location of the catheter tip. The postoperative pain relief obtained in our study is similar to that reported by Chudinov et al. (18), who demonstrated the advantage of analgesia with CPCB in comparison with systemic analgesia with meperidine in patients with hip fractures. The postoperative analgesia and satisfaction index were better in the group of patients who had CPCB during the first

32 hours after surgery. Unfortunately, the number of patients was small, the position of the catheters was not verified radiologically, and the postoperative analgesia was performed only as needed according to a protocol of pain assessment every eight hours. Patients who desired analgesia received bolus injections of 0.25% bupivacaine. Only 6.5% (5 of 77) of our patients needed rescue analgesia, which consisted of 0.1 mg/kg of morphine. The level of postoperative analgesia achieved in our patients at rest and during physiotherapy was, consequently, quite satisfactory.

There were few adverse side effects during this study. The catheters situated in the abdominal cavity and in the retroperitoneal space were associated with excessive depths of nerve stimulation (108 mm in a man who weighed 73 kg and 87 mm in a woman who weighed 51 kg). This underscores the necessity of determining the expected depth of the LP, as described in this study. The percentage of peridural analgesia was small (6.5%), in every case unilateral, and void of adverse hemodynamic consequences. The percentage of peridural anesthesia was 5% in the study by Chudinov et al. (18) (CPCB), 4% in that by Parkinson et al. (5), 9% in that by Farny et al. (12) and 10.7% in that by Stevens et al. (15) for single-shot psoas compartment blocks in adults.

In conclusion, our study demonstrates that CPCB with 0.2% ropivacaine provides optimal analgesia at rest and during physiotherapy after THA. During the 48-hour continuous infusion, we noted few unsuccessful sensory blocks in the distribution of the obturator nerve and few adverse side effects. Last, before the application of LP branch stimulation and catheter threading, the estimation of the LP depth location and of the L4 transverse process is strongly recommended.

## References

1. Bonica J. Postoperative pain. In: Bonica J, ed. The management of pain. 2nd ed. Philadelphia: Lea & Febiger, 1990:461-80.
2. Wulf H, Biscopig J, Beland B, et al. Ropivacaine epidural anesthesia and analgesia versus general anesthesia and intravenous patient-controlled analgesia with morphine in the perioperative management of hip replacement: Ropivacaine Hip Replacement Multicenter Study Group. *Anesth Analg* 1999;89:111-6.
3. Singelyn FJ, Gouverneur JMA. Postoperative analgesia after total hip arthroplasty: IV PCA with morphine, patient-controlled epidural analgesia, or continuous "3-in-1" block? A prospective evaluation by our acute pain service in more than 1,300 patients. *J Clin Anesth* 1999;11:550-4.
4. Singelyn FJ, Vanderelst PE, Gouverneur JMA. Extended femoral nerve sheath block after total hip arthroplasty: continuous versus patient-controlled techniques. *Anesth Analg* 2001;92:455-9.
5. Parkinson SK, Mueller JB, Littel WL, Bailey SL. Extent of blockade with various approaches to the lumbar plexus. *Anesth Analg* 1989;68:243-8.
6. Capdevila X, Biboulet PH, Bouregba M, et al. Comparison of the three-in-one and fascia iliaca compartment blocks in adults: clinical and radiographic analysis. *Anesth Analg* 1998;86:1039-44.

7. Marhofer P, Nasel C, Sitzwohl C, Kapral S. Magnetic resonance imaging of the distribution of local anesthetic during the three-in-one block. *Anesth Analg* 2000;90:119-24.
8. Birnbaum K, Frescher A, Hessler S, Heller KD. The sensory innervation of the hip joint: an anatomical study. *Surg Radiol Anat* 1997;19:371-5.
9. Hirst GC, Lang SA, Dust WN, et al. Femoral nerve block: single injection versus continuous infusion for total knee arthroplasty. *Reg Anesth* 1996;21:292-7.
10. Dahl JB, Anker-Moller E, Spansberg N, et al. Continuous lumbar plexus block after arthroplasty. *Anaesthesia* 1988;43:989-93.
11. Chayen D, Nathan H, Chayen M. The psoas compartment block. *1976;45:95-9.*
12. Farny J, Girard M, Drolet P. Posterior approach to the lumbar plexus combined with a sciatic nerve block using lidocaine. *Can J Anaesth* 1994;41:486-91.
13. de Visme V, Picart F, Le Jouan R, et al. Combined lumbar and sacral plexus block compared with plain bupivacaine spinal anesthesia for hip fractures in the elderly. *Reg Anesth Pain Med* 2000;25:158-62.
14. Odoom JA, Zuurmond WWA, Sih IL, et al. Plasma bupivacaine concentrations following psoas compartment block. *Anaesthesia* 1986;41:155-8.
15. Stevens RD, Van Gessel EV, Flory N, et al. Lumbar plexus block reduces pain and blood loss associated with total hip arthroplasty. *Anesthesiology* 2000;93:115-21.
16. Vaghadia H, Kapnoudhis P, Jenkins LC, Taylor D. Continuous lumbosacral block using a Tuohy needle and catheter technique. *Can J Anaesth* 1992;39:75-8.
17. Ben-David B, Lee E, Croitoru M. Psoas block for surgical repair of hip fracture: a case report and description of a catheter technique. *Anesth Analg* 1990;71:298-301.
18. Chudinov A, Berkenstadt H, Salai M, et al. Continuous psoas compartment block for anesthesia and perioperative analgesia in patients with hip fractures. *Reg Anesth Pain Med* 1999;24:563-8.
19. Gentili M, Aveline C, Bonnet F. Total spinal anaesthesia complicating posterior lumbar plexus block. *Ann Fr Anesth Réanim* 1998;17:740-2.
20. Pham-Dang C, Beaumont S, Floch H, et al. Acute toxic accident following lumbar plexus block with bupivacaine. *Ann Fr Anesth Réanim* 2000;19:356-9.
21. Aida S, Takahashi H, Shimoji K. Renal subcapsular hematoma after lumbar plexus block. *Anesthesiology* 1996;84:455-8.
22. Winnie AP, Ramamurthy S, Durrani Z, Radonjic R. Plexus blocks, for lower extremity surgery: new answers to old problems. *Anesthesiol Rev* 1974;1:11-6.
23. Farny J, Drolet P, Girard M. Anatomy of the posterior approach to the lumbar plexus block. *Can J Anaesth* 1994;41:480-5.
24. Dietemann JL, Sick H, Wolfram-Gabel R, et al. Anatomy and computed tomography of the normal lumbosacral plexus. *Neuroradiology* 1987;29:58-68.
25. Kirchmair L, Entner T, Wissel J, et al. A study of the paravertebral anatomy for ultrasound-guided posterior lumbar plexus block. *Anesth Analg* 2001;93:477-81.
26. Spansberg NLM, Anker-Moller E, Dahl JB, et al. The value of continuous blockade of the lumbar plexus as an adjunct to acetylsalicylic acid for pain relief after surgery for femoral neck fractures. *Eur J Anaesthesiol* 1996;13:410-2.
27. Fournier R, Van Gessel E, Gaggero G, et al. Postoperative analgesia with "3-in-1" femoral nerve block after prosthetic hip surgery. *Can J Anaesth* 1998;45:34-8.